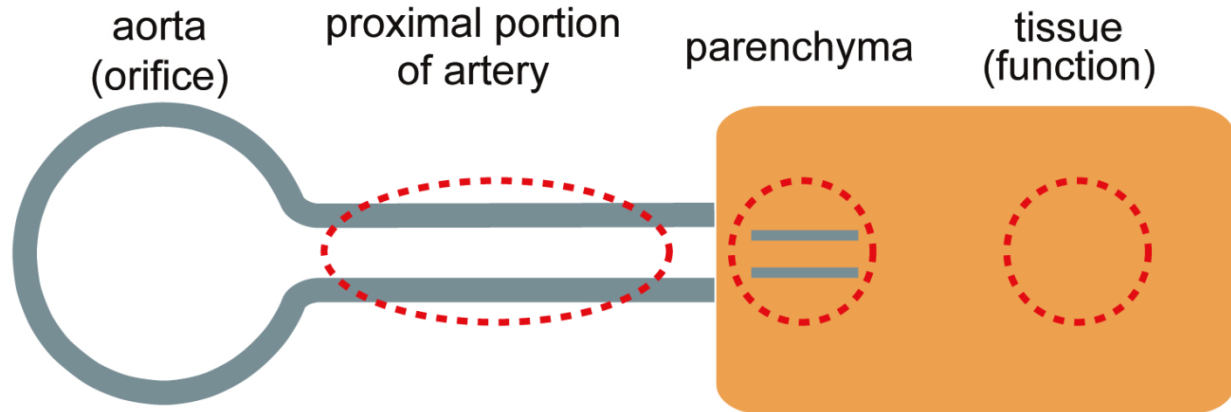


虚血：分枝灌流障害

評価部位 評価法



	aorta (orifice)	proximal portion	parenchyma	tissue (function)
myocardium	ascending aorta (TEE)	coronary artery (TEE)	N.A.	wall motion (TEE)
brain	aortic arch (TEE)	carotid artery (TEE)	orbital Doppler (echo)	NIRS, pupil, light reflex
upper extremity	aortic arch (TEE)	subclavian artery (TEE)	radial artery pressure	inspection
visceral organs	abdominal aorta (TEE)	visceral branch (TEE)	organ blood flow (TEE)	peristalsis (TEE)
lower extremity	N.A.	direct echo on femoral artery	Doppler flowmeter	inspection